

**EL PASO COUNTY CORONER
2741 EAST LAS VEGAS STREET
COLORADO SPRINGS, COLORADO 80906**

NAME: BAILEY, De'von

COUNTY: EL PASO

Date of Birth:

Age: 19

AUTOPSY NO: 19-0707

AUTOPSY DATE: 8/5/2019

Sex: M

Ht: 69.5"

Wt: 155 lbs.

BEGAN: 9:00 AM

MD: Daniel Lingamfelter, D.O.

DATE OF DEATH: 8/3/2019

TIME OF PRONOUNCEMENT: 7:20 PM

Identified by: Fingerprints

FINAL DIAGNOSIS:

I. Gunshot wound of the back (#1):

- A. Gunshot entrance wound on the lateral lower left back.
- B. Bullet perforates the skin and subcutaneous tissues, posterior left 10th rib, left lower lung, lateral left seventh rib, and penetrates the subcutaneous tissues and musculature of the lateral left chest.
- C. Recovery of a deformed/mushroomed, apparent medium-caliber, yellow metal-jacketed bullet labeled "bullet from left chest".
- D. No exit wound present.
- E. Direction of the bullet is back to front and slightly upward.
- F. Indeterminate range of gunfire (no muzzle imprint, soot, or stippling; entrance wound covered by clothing at the time of the shooting).
- G. Associated injuries: left hemothorax (750 mL), bilateral renal pallor.

II. Gunshot wound of the back (#2):

- A. Gunshot entrance wound on the lower left back.
- B. Bullet perforates the skin and subcutaneous tissues, paravertebral left 11th rib, left lower lung, posterior pericardium, posterior left ventricle of the heart, anterior left ventricle of the heart, anterior pericardium, anterior left fourth intercostal musculature, and penetrates the subcutaneous tissues and musculature of the mid chest.
- C. Recovery of a deformed/mushroomed, apparent medium-caliber, gray metal core from the anterior left fourth intercostal musculature and a deformed/mushroomed, apparent medium-caliber, yellow metal jacket from the subcutaneous tissues of the mid chest collectively labeled "bullet from mid chest".
- D. No exit wound present.
- E. Direction of the bullet is back to front and slightly upward.
- F. Indeterminate range of gunfire (no muzzle imprint, soot, or stippling; entrance wound covered by clothing at the time of the shooting).
- G. Associated injuries: left hemothorax (750 mL), bilateral renal pallor.

III. Gunshot wound of the back (#3):

- A. Gunshot entrance wound on the lower left back.
- B. Bullet perforates the skin and subcutaneous tissues, posterior left 11th intercostal musculature, left lower lung, and left diaphragm, and penetrates the spleen.
- C. Recovery of a deformed/mushroomed, apparent medium-caliber, yellow metal-jacketed bullet labeled "bullet from left diaphragm".
- D. No exit wound present.
- E. Direction of the bullet is back to front.
- F. Indeterminate range of gunfire (no muzzle imprint, soot, or stippling; entrance wound covered by clothing at the time of the shooting).
- G. Associated injuries: left hemothorax (750 mL), hemoperitoneum (trace), splenic pulverization, and bilateral renal pallor.

IV. Gunshot wound of the right arm (#4):

- A. Gunshot entrance wound on the superior right elbow.
- B. Bullet perforates the skin, subcutaneous tissues, musculature, and grazes the underlying bone before exiting.
- C. Exit wound on the lateral right elbow.
- D. No projectile or projectile fragments recovered.
- E. Direction of the bullet is downward and slightly ulnar to radial.
- F. Distant range of gunfire (no muzzle imprint, soot, or stippling).

V. Other injuries:

- A. Contusion, above lateral right brow.
- B. Abrasion, anterior left knee.
- C. Area of abrasions, inferolateral aspect of left knee.

VI. History that the subject was shot by law enforcement.


OPINION: It is my opinion that De'von Bailey, a 19-year-old black male, died as a result of multiple gunshot wounds. The wounds collectively perforated the heart, left lung, diaphragm, and penetrated the spleen, resulting in massive blood loss and his subsequent death. Investigation and autopsy findings are consistent with these injuries being the result of the actions of another person or persons.

MANNER OF DEATH: Homicide.


DANIEL LINGAMFELTER, D.O.


TRAVIS DANIELSEN, M.D.


EMILY RUSSELL, M.D.


LEON KELLY, M.D.
August 15, 2019

PERSONS PRESENT AT AUTOPSY

Christian Liewer, Brent Jacobsen, and Amanda Kimball of the Colorado Springs Police Department Crime Lab, Nickolas Brklich of the El Paso County Sheriff's Office, and Reggy Short, Kenneth Larsen, and Elizabeth Robinson of the District Attorney's Office are present for the postmortem examination.

GENERAL EXAMINATION

The body is that of a normally-developed, well-nourished, black male teenager who weighs 155 lbs, is 69-1/2 inches in length, and appears compatible with the reported age of 19 years. An El Paso County Coroner identification band is around the left ankle.

The body is received unclad. A pair of cut camouflage-pattern underwear is underneath the body. Two black socks and a left-sided blue and white shoe in brown paper bags accompany the body.

The body is received with the hands bagged.

Multiple radiographic scans are taken and examined. Three bullets are identified within the left side of the torso, consistent with the recovered projectiles. Minimal bullet debris is present in the region of the right elbow.

Swabs from the face, neck, and hands, bilateral fingernail clippings, a gunshot residue (GSR) kit, a DNA blood card, a set of 10 fingerprints, and a set of palm prints are collected.

All evidence collected at the time of autopsy (Colorado Division of Motor Vehicles record, 2 black socks, a blue and white shoe, multicolored underwear, swabs from face, swabs from neck, swabs from right hand, swabs from left hand, fingernails from right hand, fingernails from left hand, left and right hand bags, GSR kit, DNA blood card, a set of 10 fingerprints, palm print from left hand, palm print from right hand, bullet from mid chest, bullet from left diaphragm, and bullet from left chest) is released to Amanda Kimball of the Colorado Springs Police Department Crime Lab.

EXTERNAL EXAMINATION

There is good preservation in the absence of embalming. Rigor mortis is fully developed in all extremities and the jaw. Fixed dark pink lividity extends over the posterior body surfaces, except in areas exposed to pressure. The deceased has black, tightly curly scalp hair averaging 2 inches in maximum length. The irides appear brown; the corneae are clear; and there are no petechiae of the bulbar or palpebral surfaces of the conjunctivae. The ears, nose, lips, and external auditory canals are unremarkable. The mouth has natural teeth in fair condition. The decedent has a black mustache and beard. The external genitalia and perineum are unremarkable.

The chest is covered in dark ink tattoos including a web-like design, "CR", and "EST 1999". A 5-1/2 inch dark ink tattoo of "Delisha" is on the medial upper right arm. A 3-1/2 inch dark ink tattoo of "Interstate 25 Colorado" is on the ventral right forearm. An 8 inch dark ink tattoo of

“Respect” extends down the posterior upper right arm. A 9-1/2 inch dark ink tattoo of “Loyalty” covers the posterior upper left arm. A 3 inch dark ink tattoo of “Greg” is on the medial upper left arm. A 3 inch dark ink tattoo of “NLMB” is immediately above the left antecubital fossa. The left forearm is covered in dark ink tattoos including what resembles the Monopoly Man and “Family”.

A 2-3/4 inch oblique linear scar is on the dorsal right foot.

Besides the evidence of medical therapy and injury to be described, the remainder of the external examination of the body is unremarkable.

EVIDENCE OF MEDICAL THERAPY

A medical identification band is around the right wrist. An endotracheal tube extends from the oral cavity. White gauze is taped over the eyes. A cervical collar surrounds the neck. EKG tabs are on the body. Intraosseous needles extend from the lateral right shoulder and upper right shin. A blood pressure cuff is around the upper right arm. A tension pneumothorax catheter extends from the inferolateral right chest. White bandaging surrounds the right antecubital fossa. A pulse oximeter is on the tip of the right index finger.

A 9-1/4 inch horizontal linear sutured surgical incision, consistent with a thoracotomy, extends across the left chest, passing immediately below the left nipple and through the left fifth intercostal musculature.

EVIDENCE OF INJURY

I. GUNSHOT WOUND OF THE BACK (#1)

A 3/8 inch round gunshot entrance wound is on the lateral lower left back, centered 21-1/4 inches below the top of the head and 5 inches left of the posterior midline. The wound bears a 1/16 inch circumferential marginal abrasion. No muzzle imprint, soot, or stippling is present.

After perforating the skin and subcutaneous tissues, the bullet sequentially perforates the posterior left 10th rib (3.5 cm defect), left lower lung (10 x 3 cm aggregate of multiple defects), lateral left seventh rib (3.8 cm defect), and penetrates the subcutaneous tissues and musculature of the lateral left chest.

Injuries associated with the gunshot wound include left hemothorax (750 mL) and bilateral renal pallor.

Recovered from the subcutaneous tissues and musculature of the lateral left chest, at a location 19-1/4 inches below the top of the head and 5-1/2 inches left of the anterior midline, is a deformed/mushroomed, apparent medium-caliber, yellow metal-jacketed bullet labeled “bullet from left chest”. A 4 inch dark pink-gray contusion overlies the recovery site.

No exit wound is present.

The direction of the bullet is back to front and slightly upward.

II. GUNSHOT WOUND OF THE BACK (#2)

A 3/8 inch round gunshot entrance wound is on the lower left back, centered 21-3/8 inches below the top of the head and 2-1/2 inches left of the posterior midline. The wound bears a 1/16 inch circumferential marginal abrasion. No muzzle imprint, soot, or stippling is present.

After perforating the skin and subcutaneous tissues, the bullet sequentially perforates the paravertebral left 11th rib (3.2 cm defect), left lower lung (10 x 3 cm aggregate of multiple defects), posterior pericardium, posterior left ventricle of the heart (5.5 cm defect), anterior left ventricle of the heart (3.5 cm defect), anterior pericardium, anterior left fourth intercostal musculature (1.5 cm defect), and penetrates the subcutaneous tissues and musculature of the mid chest.

Injuries associated with the gunshot wound include left hemothorax (750 mL) and bilateral renal pallor.

A deformed/mushroomed, apparent medium-caliber, gray metal core is recovered from the anterior left fourth intercostal musculature, and a deformed/mushroomed, apparent medium-caliber, yellow metal jacket is recovered from the subcutaneous tissues of the mid chest, immediately anterior to the core. The recovery location is centered 17-1/4 inches below the top of the head and 1-1/4 inches left of the anterior midline. A 1 inch dark pink-gray contusion overlies the recovery site. The core and jacket are collectively labeled "bullet from mid chest".

No exit wound is present.

The direction of the bullet is back to front and slightly upward.

III. GUNSHOT WOUND OF THE BACK (#3)

A 1/4 inch round gunshot entrance wound is on the lower left back, centered 23 inches below the top of the head and 3-1/4 inches left of the posterior midline. The wound bears a 1/16 inch circumferential marginal abrasion. No muzzle imprint, soot, or stippling is present.

After perforating the skin and subcutaneous tissues, the bullet sequentially perforates the posterior left 11th intercostal musculature (2.5 cm defect), left lower lung (10 x 3 cm aggregate of multiple defects), left diaphragm (7.0 cm defect), and penetrates the spleen.

Injuries associated with the gunshot wound include left hemothorax (750 mL), trace hemoperitoneum, splenic pulverization, and bilateral renal pallor.

Recovered from the left diaphragm, at a location 23-1/4 inches below the top of the head and 3

inches left of the anterior midline, is a deformed/mushroomed, apparent medium-caliber, yellow metal-jacketed bullet labeled "bullet from left diaphragm".

No exit wound is present.

The direction of the bullet is back to front.

IV. GUNSHOT WOUND OF THE RIGHT ARM (#4)

A 3/8 inch round gunshot entrance wound is on the superior right elbow, centered 12-3/4 inches below the top of the right shoulder and within the posterior midline of the right arm. The wound bears a 1/16 to 1/8 inch circumferential marginal abrasion. No muzzle imprint, soot, or stippling is present.

The bullet perforates the skin, subcutaneous tissues, musculature, and grazes the underlying bone before exiting.

A 1-1/2 inch irregular gunshot exit wound is on the lateral right elbow, centered 13-1/4 inches below the top of the right shoulder and 1-1/4 inches lateral to the posterior midline of the right arm. A 1/2 inch to 3/4 inch-wide dark pink-red marginal abraded contusion spans the 12:00 to 6:00 positions, clockwise.

No projectile or projectile fragments are recovered.

The direction of the bullet is downward and slightly ulnar to radial.

V. OTHER INJURIES

A 1/4 inch dark pink-gray contusion is immediately above the lateral right brow.

A 1/4 inch dark red abrasion is on the anterior left knee. A 3-1/4 inch area of dark red-tan abrasions is on the inferolateral aspect of the left knee.

INTERNAL EXAMINATION

HEAD: The scalp is incised and retracted. The scalp, subscalpular area, and skull are unremarkable. The cranial vault is opened revealing thin, tough, pliable dura and no hemorrhage in the epidural, subdural, or subarachnoid space. The cerebrospinal fluid is clear. The brain weighs 1400 gm and the cerebral hemispheres, midbrain, and pons are symmetrical and grossly unremarkable. On cross-section of the brain parenchyma, there is no evidence of infection, tumor, or trauma. The dura is stripped from the basilar skull and no fractures are found. The cervical spinal column is stable upon internal palpation.

BODY: The body is opened with a Y-shaped incision. The organs occupy their usual positions and relationships. The body cavities are free of adhesions. The right pleural cavity and the perforated pericardial cavity contain no abnormal collections of fluid.

NECK: The hyoid bone and larynx are intact. The airway is patent and there is no evidence of infection or tumor. The thyroid gland and tongue are unremarkable.

CARDIOVASCULAR SYSTEM: The intimal surface of the abdominal aorta is free of significant atherosclerosis. The heart weighs 210 gm. The epicardial and endocardial surfaces are smooth and glistening in uninjured areas. The myocardium is uniformly firm and has a homogeneous, beefy-red appearance in areas without injury. The cardiac valves are thin, delicate, and unremarkable. The coronary arteries are free of significant atherosclerosis.

LUNGS: The right lung weighs 225 gm and the left lung weighs 210 gm. The major bronchi are unremarkable. The pleural surfaces are smooth and glistening and have a purple-red appearance in areas without injury. On cross-section, the parenchyma appears dark pink in uninjured areas. There are no pulmonary emboli.

GASTROINTESTINAL SYSTEM: The esophagus, stomach, small and large bowel, and appendix are unremarkable. The stomach contains a trace amount of tan fluid.

LIVER: The liver weighs 1075 gm. The capsule is smooth and glistening. The parenchyma is dark brown-red. The gallbladder contains 40 mL of yellow-brown, viscid bile without calculi.

PANCREAS: Unremarkable.

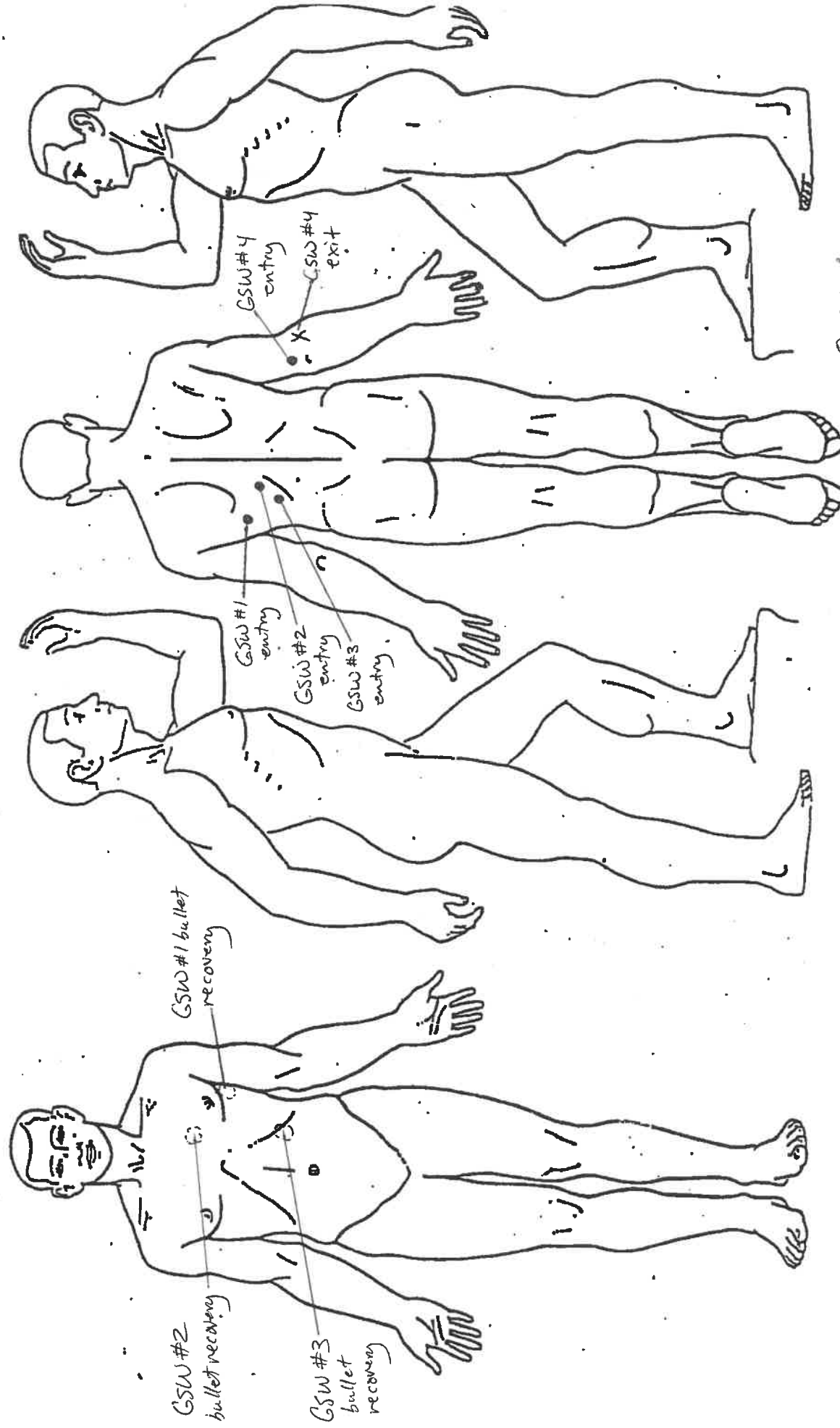
ADRENAL GLANDS: Unremarkable.

SPLEEN: The pulverized spleen weighs 55 gm.

GENITOURINARY SYSTEM: The right kidney weighs 75 gm and the left kidney weighs 110 gm. The capsules strip with ease revealing smooth, light brown cortical surfaces. On cross-section, the cortices exhibit well-demarcated corticomedullary junctions. The collecting systems, ureters, and bladder are unremarkable. The urinary bladder contains 250 mL of clear-yellow urine. The prostate is unremarkable.

Name: De'von Bailey Case#: 19-00707

Color: Black Age: 19 Years Gender: Male Date: 08/05/2019



Daniel Fitzgerald, D.O.

GSW = gunshot wound
OOR EXTERNAL - 0910 BODY FOUR
VIEW

Toxicology Report
El Paso County Coroner's Office
2741 E. Las Vegas Street, Colorado Springs, CO 80906
719-390-2450 MAIN/719-390-2462 FAX

Name: BAILEY, Devon
Doctor: Daniel Lingamfelter D.O.
County: El Paso

Case #: 19-00707
Date Received: 08/05/2019
Agency#:

Alcohols and volatiles:

Analyte	Specimen	Result
ETHANOL	Vitreous	Negative
ETHANOL	Cavity Blood	73 mg/dL

Immunoassay screens (ELISA):

Analyte	Specimen	Result
AMPHETAMINE	Urine	Negative
BARBITURATES	Urine	Negative
BENZODIAZEPINE METABOLITES	Urine	Negative
COCAINE/ BENZOYLECGONINE	Urine	Negative
FENTANYL	Urine	Negative
METHADONE	Urine	Negative
METHAMPHETAMINE	Urine	Negative
OPIATES	Urine	Negative
OXYCODONE	Urine	Negative
THCCOOH	Urine	Positive
TRAMADOL	Urine	Negative
TRICYCLIC ANTIDEPRESSANTS	Urine	Negative
ZOLPIDEM	Urine	Negative

GC-MS results (Qualitative)

Analyte	Specimen	Result
THCCOOH	Urine	Present
COTININE	Urine	Present

Toxicology Report
El Paso County Coroner's Office
2741 E. Las Vegas Street, Colorado Springs, CO 80906
719-390-2450 MAIN/719-390-2462 FAX

Name: BAILEY, Devon
Doctor: Daniel Lingamfelter D.O.
County: El Paso

Case #: 19-00707
Date Received: 08/05/2019
Agency#:

Quantitative Results

Analyte	Specimen	Result
---------	----------	--------

Miscellaneous results

Analyte	Specimen	Result
---------	----------	--------

Comments:

Reviewed by: Werner Jenkins MS **Date released:** 08/15/19 **Reviewed By:** Daniel Lingamfelter D.O.



Reviewer Signature



Reviewer Signature